

Hip arthroscopy and femoroacetabular impingement

HERE TO STAY OR GONE

With the current explosion in hip arthroscopy procedures, patients are being referred in increasing numbers for the evaluation of hip pain. Many of these patients engage in athletic activity and are unwilling to limit their activity. As a result, the understanding of the functional anatomy of this joint has been improved and refined. Concurrently, the advancement of MRI has enabled the diagnosis of soft tissue causes of hip pain to be greatly enhanced. Consequently, the differential diagnosis of hip pain has been broadened and treatment vastly improved.

Historically, hip pain was treated with prolonged conservative management and activity restriction. Open procedures were considered if that failed, but with the advent of hip arthroscopy the landscape has been changed; large numbers of patients are enjoying the advantages of arthroscopic treatment and returning to their full activities quickly. It is best to think of the causes of hip pain as intra-articular, extra-articular and causes that mimic hip pain (see below). Arthroscopy can be used to treat both intra- and extra-articular causes but not all of them.

Femoroacetabular impingement

Femoroacetabular impingement (FAI), a hidden disorder until the current decade, has received significant attention as it has now been established that it is a cause of hip joint osteoarthritis. Therefore, early diagnosis and treatment of this condition might prevent or delay the onset of osteoarthritis. Put simply, FAI is an abutment conflict between the bone of the femur and that of the pelvis.

The causes of impingement in the hip can be developmental (Perthes, slipped upper femoral epiphysis) or can arise from post-traumatic or post osteotomy changes in structural anatomy.

Three main types of impingement (figure 1) have been described: CAM impingement results from abnormalities at the femoral head-neck junction impacting the acetabulum causing labral and chondral damage (more common in young males). Pincer impingement results from acetabular over coverage, (e.g. acetabular retroversion (figure 2), coxa profunda or protrusio), resulting in impingement of a normal femoral head-neck junction, on the acetabular rim (more common in middle-aged females). The mixed form is a combination of the two, thought to be the commonest. Approximately 25% of the population are thought to demonstrate radiographic features of FAI but only 5-10% are symptomatic. Bilaterality of radiographic features does not necessarily equate to bilateral symptoms.

Each type causes repetitive microtrauma to the labrum and/or articular cartilage, resulting in distinct patterns of injury. In pincer impingement, an indentation at a normal femoral head-neck junction, caused by repeated abutment against the anterior acetabular margin and an ossified labrum is seen.

The shear forces in CAM impingement produce an outside-in abrasion of the acetabular cartilage and/or its avulsion from the labrum and the subchondral bone in the anterosuperior rim area. Arthritis develops when damage at the labral-cartilage junction extends to the articular cartilage and subchondral bone.

Clinical features of FAI

A young or middle-aged patient, who describes the gradual onset of unilateral hip pain that is predominantly in the groin, must be considered to have femoroacetabular impingement. The patient may report mechanical symptoms (locking, catching) indicative of a labral tear, or a delamination injury of the articular cartilage. The pain is often intermittent and exacerbated by an excessive demand on hip flexion, such as occurs with athletic activities and in very flexible hips.

The most important physical finding is the result of the impingement test, which reveals limitation of internal rotation and adduction in flexion out of proportion with limitations of other motions. With the patient supine, the hip is internally rotated as it is passively flexed to approximately 90° and adducted. Flexion and adduction cause abutment of the femoral neck on the acetabular rim. Further passive internal rotation induces shear forces at the labrum and can create a sharp pain when there is a labral and/or a chondral lesion.

Investigation of FAI

Plain radiographs are the most important imaging studies for the diagnosis of FAI. Recommended radiographs are an anteroposterior view and cross-table lateral view of the hip in 15 degrees of internal rotation.

Further investigation using CT, allows three-dimensional reconstruction of the hip joint - for detailed definition of femoral head-neck asphericities that cause osseous impingement, as well as determination of the version of the femoral neck and acetabulum.

Gadolinium enhanced MRI is needed to assess labral (figure 3) and chondral injury, as well as to demonstrate the contour of the femoral head-neck junction.

Treatment options

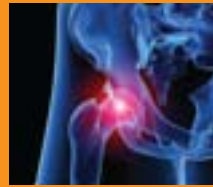Non-operative

This may include modification of activity, restriction of athletic pursuits, and reduction of excessive demand on the hip. Non-steroidal anti-inflammatory medication may

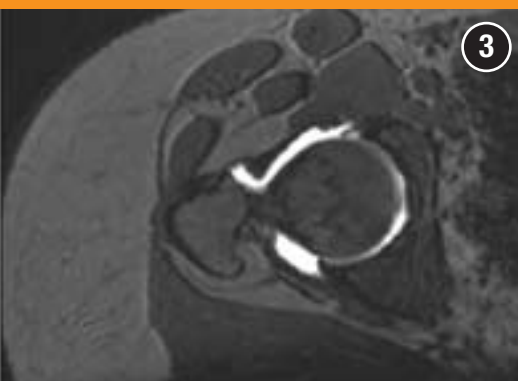
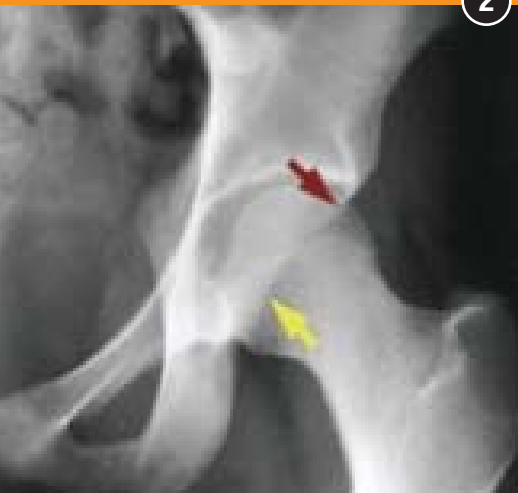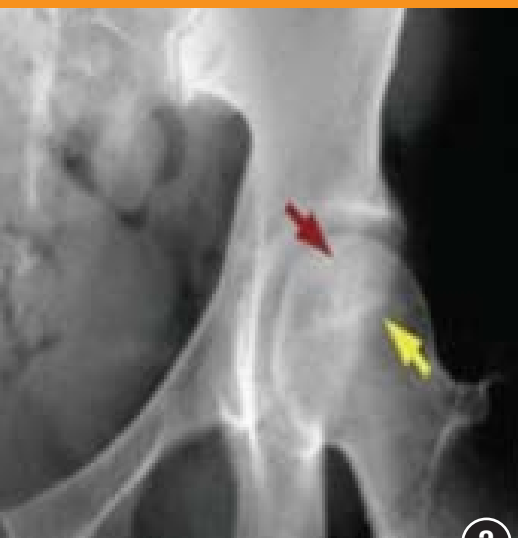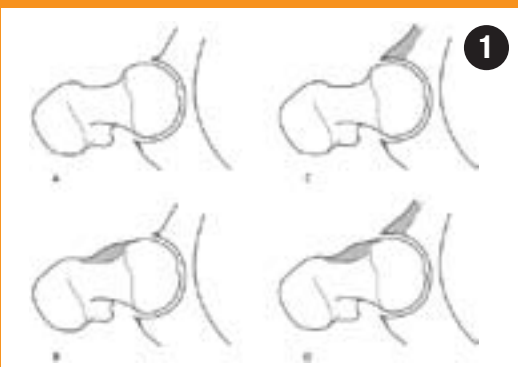
Intra-articular	Extra-articular	Mimickers of hip pain
Femoroacetabular impingement	Iliopsoas tendinitis	Osteitis pubis
Labral tears	Iliotibial band syndrome	Sports hernia
Loose bodies	Trochanteric bursitis	Obturator neuropathy
Ligamentum teres rupture	Gluteus medius/minimus tendinosis	
Chondral damage	Piriformis syndrome	
Capsular laxity	Stress fracture	
	Adductor strain	
	Sacroiliac joint pathology	

Causes of pain around the hip joint

TOMORROW?



■ Mr Rahul Patel is a Consultant Orthopaedic Surgeon at UCLH and The Wellington Hospital.



relieve the pain. Physical therapy should emphasise muscle strengthening and avoidance of extremes of range of motion. The young age, coupled with high activity levels of these patients, usually jeopardises compliance with non-operative treatment. Hip impingement is a mechanical problem and non-operative measures will not eliminate the pathomechanics of structural deformities.

Operative

Operative treatment focuses on improving the clearance of hip motion and alleviating femoral abutment against the acetabular rim, which will relieve the pathological changes in the labrum and articular cartilage. Arthroscopy is becoming an increasingly popular method to treat FAI because of the obvious advantages of arthroscopic surgery. As technological advances are being made to improve the specialised equipment, better outcomes are being achieved. However, if there is damage to the articular cartilage this may compromise the result of operative treatment. Thus early diagnosis and treatment is paramount to success.

Arthroscopy (figure 4) essentially is divided into two phases: central compartment arthroscopy allows visualisation and treatment of articular surface and labrum pathologies, including removal of loose bodies, labral repair, chondroplasty and microfracture. Peripheral compartment arthroscopy refers to the femoral head-neck junction area, where non-spherical aspects of the femoral head are

corrected using high-speed burrs and shavers. Acetabular abnormalities can be addressed during either phase, commonly involving reducing bony over-coverage anteriorly using high-speed burrs.

Post-operatively, weight bearing is usually restricted for four weeks to decrease the risk of femoral neck fracture, but use of stationary bicycles and swimming is encouraged after two weeks. Most patients only require an overnight stay and some centres manage the procedure as a day case.

The early results of hip arthroscopy are promising in terms of symptom and functional improvement. We have no knowledge yet of the ability of this operative technique to alter the course towards total hip replacement, but this will become apparent in time.

In summary, patients with hip and groin pain can be a diagnostic headache. Careful examination and investigation utilising a variety of modalities will usually reveal the pathology, but can be time consuming. FAI is one of the more common diagnoses seen and is usually excluded first by simple examination and radiology. Because FAI is believed to be a precursor to osteoarthritis, if it is suspected, early referral to a specialist is strongly recommended as early diagnosis and treatment using hip arthroscopy appears to yield promising outcomes.

Here to stay... for now!

Figures

1: Biomechanics of hip impingement seen on axial view of hip joint. A: normal hip. B: CAM. C: excessive over-coverage of femoral head – pincer impingement. D: mixed.

2: Red arrow indicates anterior acetabular wall and yellow arrow indicates posterior acetabular wall. **Top:** this is the normal relationship in an anteverted acetabulum. **Bottom:** Note the “crossover” of the wall margins: acetabular retroversion

3: MRI scan demonstrating labral tear

4: Hip arthroscopy with instruments in anterior and anterolateral portals.

